

# A case of superior vena cava syndrome caused by colon cancer treated with bevacizumab combination chemotherapy

ÖZLEM YAVAŞ, ÖNDER EREN, MEHMET ARTAÇ, CEM BÖRÜBAN, MİNE GENÇ

Selçuk University Meram Medical School, Department of Medical Oncology, Konya-Turkey

## ABSTRACT

Metastasis of colon cancer to the mediastinal lymph nodes is extremely rare. Herein we report a case of superior vena cava syndrome caused by mediastinal lymph node metastasis of colon cancer and treated by radiotherapy and bevacizumab with chemotherapy. [Turk J Cancer 2009;39(1):115-116]

**KEY WORDS:** Superior vena cava syndrome, colon cancer, mediastinal lymph nodes

## INTRODUCTION

Vena cava superior syndrome is caused by obstruction of blood flow through superior vena cava. The obstruction may be due to extrinsic compression, invasion or thrombus formation (1,2). Malignant disease is the most common cause of superior vena cava syndrome. Lung cancers, especially small cell carcinomas and lymphomas are the most common malignancies causing superior vena cava obstruction (1,2). Colon cancers can spread to regional lymph nodes, liver or lung but metastasis to the mediastinal lymph nodes is unusual (3). Superior vena cava obstruction due to colon cancer metastasis is rarely reported in literature (3-5). Herein we present a patient with superior vena cava syndrome caused by colon cancer metastasis in whom long term survival has been achieved with palliative radiotherapy and chemotherapy.

## Case Report

A 57 year-old man with a diagnosis of colon cancer presented with facial edema and dyspnea existing for two months. His past history also revealed coronary artery heart disease, type II diabetes mellitus, and right sided hemicolectomy for caecal adenocarcinoma. The pathologic stage was Dukes C1 and six cycles of adjuvant chemotherapy with 5 FU and leucovorin were given. He was not on routine control for his cancer. On physical examination facial edema, jugular vein distention and conglomerated lymphadenopathy of about 5 cm diameter in the right supraclavicular region were detected. Computed tomography of the chest revealed multiple mediastinal lymphadenopathy, the largest 4 cm in diameter, compressing the superior vena cava. There were no abnormalities in lung parenchyma (Figure 1). Computed tomography of the abdomen was normal. Excisional biopsy of supraclavicular lymphadenopathy revealed metastatic adenocarcinoma staining strongly positive for CEA. Serum tumor markers including CEA and CA 19-9 were high. Emergent palliative radiation to the mediastinal lymph nodes provided symptomatic relief. Two weeks after radiotherapy, Folfox-4 regimen was started. While there was substantial subjective response, the mediastinal lymph nodes progressed after 5 cycles of chemotherapy. The patient developed signs of facial edema and swelling again. The combination of bevacizumab with irinotecan, 5 FU and leucovorin (IFL regimen) was instituted. Signs

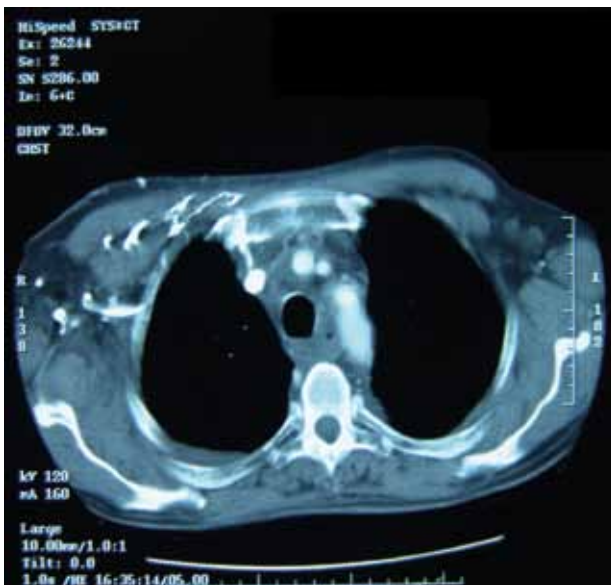


Fig 1. Computed tomography of the chest

and symptoms of vena cava obstruction clearly improved after 2 cycles of chemotherapy. Minimal regression of mediastinal lymphadenopathy was detected on computed tomography of the chest. He received this regimen during 15 months without symptom and signs of progression.

## DISCUSSION

Superior vena cava obstruction may be caused by various malignancies (1,2). The most common malignancies that cause vena cava obstruction are lymphomas and lung cancers (1,2). Vena cava obstruction due to colon cancer is rarely reported in literature (3-5). Radiotherapy, chemotherapy, endovascular stent application and surgery may be performed for treatment (6,7). Radiotherapy provided quick symptom relief in our patient. The patient is still alive and without progression after diagnosis of metastatic disease by using combination chemotherapy with bevacizumab. Therefore multimodality treatment options should be considered for treatment of metastatic colon cancer.

Although, there have been some reports about bevacizumab related thrombosis in colorectal cancer, IFL-bevacizumab has effectively relieved signs and symptoms of vena cava superior obstruction due to metastatic lymph nodes and maintain long term progression free survival with no evidence of thrombosis (8). To our knowledge, this is the first report about the treatment of cancer-related SVCS with bevacizumab.

## References

1. Joachim Yahalom. Oncological Emergencies. In: Vincent T. De Vita, Jr., Samuel Hellman, Steven A. Rosenberg, editors. *Cancer Principles & Practice of Oncology*. Lippincot Williams and Wilkins, 2005;2273-80.
2. Costovici CN, Badulescu F. Superior vena cava syndrome. In: Paris A. Kosmidis, Dick Schrijvers, Fabrice Andre, Sylvie Rottey, editors. *Handbook of Oncological Emergencies*. Taylor&Francis, 2005;18-24.
3. Kuba H, Sato N, Uchiyama A, et al. Mediastinal lymph node metastasis of colon cancer: report of a case. *Surg Today* 1999;29:375-7.
4. Nakahara O, Beppu T, Ishiko T, et al. A long-term survival case of liver and mediastinal LN metastases from colon cancer treated with intensive multimodal therapy. *Gan To Kagaku Ryoho* 2006;33:1792-4.
5. Dendo S, Inaba Y, Arai Y, et al. Severe obstruction of the superior vena cava caused by tumor invasion. Recanalization using a PTFE-covered Z stent. *J Cardiovasc Surg (Torino)* 2002;43:287-90.
6. Rowell NP, Gleeson FV. Steroids, radiotherapy, chemotherapy and stents for superior vena caval obstruction in carcinoma of the bronchus: a systematic review. *Clin Oncol (R Coll Radiol)* 2002;14:338-51.
7. Kvale PA, Simoff M, Prakash UB. American College of Chest Physicians. Lung cancer. Palliative care. *Chest* 2003;123(1 Suppl):284S-311S.
8. Hurwitz H, Saini S. Bevacizumab in the treatment of metastatic colorectal cancer: safety profile and management of adverse events. *Semin Oncol* 2006;33(5Suppl 10):S26-34.