

# Primary uterosacral ligament müllerian adenosarcoma associated with endometriosis: A case report

SEYRAN YİĞİT<sup>1</sup>, MEHMET ALİ UYAROĞLU<sup>1</sup>, ZUHAL KUŞ<sup>1</sup>, DİLEK UYSAL<sup>2</sup>

Atatürk Training and Research Hospital, Departments of <sup>1</sup>Pathology and <sup>2</sup>Gynecology&Obstetrics İzmir-Turkey

## ABSTRACT

Extrauterine müllerian adenosarcoma is rare and is thought to arise from endometriotic deposits or pluripotent mesothelial and mesenchymal cells of the pelvic cavity. We presented a 23 year -old female with a large pelvic mass. Laparotomy and intraoperative consultation were performed. Histologically, mass revealed endometriosis foci and diagnostic appearance of Müllerian adenosarcoma. The possibility of adenosarcoma should be considered if an enlarging mass occurs at the side of extraovarian endometriosis. [Turk J Cancer 2009;39(4):155-157]

**KEY WORDS:** Adenosarcoma, extraovarian, endometriosis

## INTRODUCTION

Endometriosis has long been recognized to undergo pathological changes similar to those seen in the endometrium (1). Malignancy arising in endometriosis is rare and occurs in less than 1% of cases (2). Among these tumors, most common types, which are of epithelial origin are endometrial adenocarcinoma and clear cell carcinoma (3,4). Only a limited number of stromal tumors such as adenosarcoma have been reported to date.

We present a case of müllerian adenosarcoma arising from endometriosis of the uterosacral ligament.

## CASE REPORT

A 23-year old nulliparous female was admitted to the hospital with inguinal pain. Ultrasonography showed a 124x77 mm mass which composed of solid and cystic areas. Doppler ultrasonography findings were more likely concordant with malignancy.

She had undergone exploratory laparotomy. Laparotomy revealed a large pelvic mass that extended into the left uterosacral ligament and retroperitoneum. For intraoperative examination, two masses were received in our pathology laboratory, measuring 6x4x3cm and 7x4x2cm. Both of them had solid and cystic components. Cystic component showed papillary projections. The masses were reported as endometriosis with frozen sections.

Multiple sections were taken for routine histological examination and stained with hematoxylin and eosin. In the permanent blocks, in addition to endometriosis foci, benign appearing müllerian type glands associated with sarcomatous stroma that formed surface papillae (leaf-like pattern) were noticed (Figures 1 and 2). Sarcomatous component displayed mild nuclear atypia and mitotic activity averaging 3 mitoses per 10 HPF (Figure 3). Stromal cuffing of the glands was noted focally. These findings showed that the tumor was a müllerian adenosarcoma which was closely related to endometriosis. Immunohistochemically, the tumor had a high proliferation index with Ki67 (Figure 4).

External radiotherapy was decided for the patient, but she refused adjuvant therapy.

## DISCUSSION

Malignant tumors that arise from within ectopic endometrium are thought to be rare. One large series reported

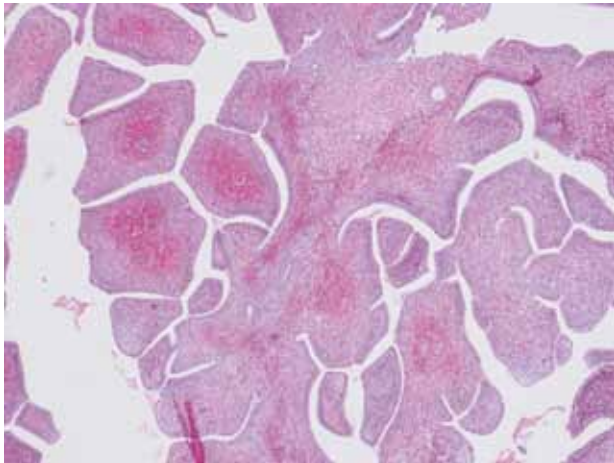


Fig 1. Typical leaf-like pattern in adenosarcoma

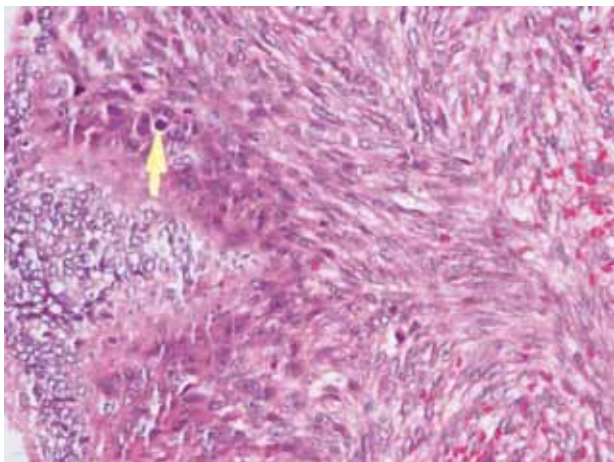


Fig 2. Endometriosis associated with the adenosarcoma

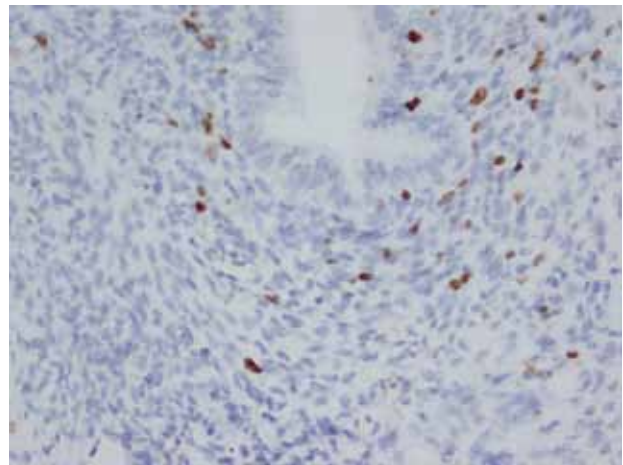


Fig 3. Stromal atypia and mitosis

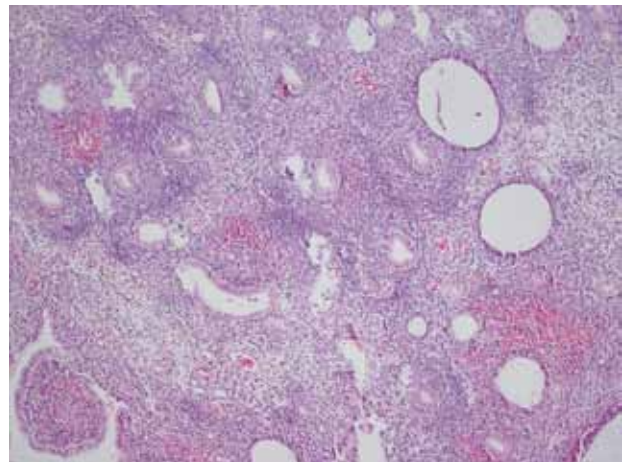


Fig 4. The labelling index for Ki 67 is increased up to 10% stromal component

1323 cases of endometriosis which they found malignancy to arise in %0.9 of them (1). Thirty-six percent of those endometriosis specimens were from the ovary, while only 2% were from uterosacral ligament. In the same study, three extragonadal sarcomas arose in endometriosis were reported.

Müllerian adenosarcoma arising from the extraovarian sites have been described (2,3, 5-9). To our knowledge, this is the first case of adenosarcoma arising from endometriosis of the uterosacral ligament in the literature.

The histogenesis of the extrauterine müllerian adenosarcoma is unclear. It may arise from a focus of endometriosis as in this case. Müllerian adenosarcomas arising in endometriosis can be incompletely diagnosed as endometriosis, especially during an intraoperative consultation.

Clement and Scully (10) have recommended that, adenosarcoma can be diagnosed when one or more of the

following criteria are present: 1) stromal mitotic count of two or more per 10 HPF, 2) marked stromal cellularity, 3) more than a mild degree of stromal atypia.

Extrauterine müllerian adenosarcomas occur in younger women and are more aggressive than uterine counterparts (7).

The main reason that patients with ovarian adenosarcomas have poorer prognosis than those with uterine sarcomas is probably related to the location of the tumors

with respect to the abdominal cavity and the lack of an anatomic barrier to spread.

Surgery is the mainstay of treatment. Müllerian adenosarcomas in general can be expected to recur or metastasize locally. In our case, external radiotherapy was decided but she refused adjuvant therapy. The patient is free of tumor one year postoperatively.

In conclusion, although it's rare, malignant degeneration to adenosarcoma in endometriosis cases should be kept in mind.

---

## References

1. Stern RC, Dash R, Bentley RC, et al. Malignancy in endometriosis: frequency and comparison of ovarian and extraovarian types. *Int J Gynecol Pathol* 2001;20(2):133-9.
2. Jelovsek JE, Winans C, Brainard J, et al. Endometriosis of the liver containing müllerian adenosarcoma: case report. *Am J Obstet Gynecol* 2004;191(5):1725-7.
3. Raffaelli R, Piazzola E, Zanconato G, et al. A rare case of extrauterine adenosarcoma arising in endometriosis of the rectovaginal septum. *Fertil Steril* 2004;81(4):1142-4.
4. Hitti IF, Glasberg SS, Lubicz S. Clear cell carcinoma arising in extraovarian endometriosis: report of three cases and review of the literature. *Gynecol Oncol* 1990;39(3):314-20.
5. Liu L, Davidson S, Singh M. Mullerian adenosarcoma of vagina arising in persistent endometriosis: report of a case and review of the literature. *Gynecol Oncol* 2003;90(2):486-90.
6. Anderson J, Behbakht K, De Geest K, et al. Adenosarcoma in a patient with vaginal endometriosis. *Obstet Gynecol* 2001;98(5 Pt 2):964-6.
7. Chang HY, Changchien CC, Chen HH, et al. Extrauterine mullerian adenosarcoma associated with endometriosis and rectal villotubular adenoma: Report of a case and review of the literature. *Int J Gynecol Cancer* 2005;15(2):361-5.
8. Dincer AD, Timmins P, Pietrocola D, et al. Primary peritoneal mullerian adenosarcoma with sarcomatous overgrowth associated with endometriosis: a case report. *Int J Gynecol Pathol* 2002;21(1):65-8.
9. Eichhorn JH, Young RH, Clement PB, et al. Mesodermal (mullerian) adenosarcoma of the ovary: a clinicopathologic analysis of 40 cases and a review of the literature. *Am J Surg Pathol* 2002;26(10):1243-58.
10. Clement PB, Scully RE. Mullerian adenosarcoma of the uterus. A clinicopathologic analysis of 100 cases with a review of the literature. *Hum Pathol* 1990;21:363-81.